


(\*del RadioGraphics y el Instituto de Patología de las Fuerzas Armadas)

\*Resúmenes enviados y publicados con autorización de la RSNA.



## From the archives of the AFIP Lung Disease in Premature Neonates: Radiologic-Pathologic Correlation<sup>1</sup>

Geoffrey A. Agrons, MD • Sherry E. Courtney, MD • J. Thomas Stocker, COL, MC, USA • Richard I. Markowitz, MD


Pulmonary disease is the most important cause of morbidity in preterm neonates, whose lungs are often physiologically and morphologically immature. Surfactant deficiency in immature lungs triggers a cascade of alveolar instability and collapse, capillary leak edema, and hyaline membrane formation. The term *respiratory distress syndrome* (RDS) has come to represent the clinical expression of surfactant deficiency and its nonspecific histologic counterpart, *hyaline membrane disease*. Historically, chest radiographs of infants with RDS predictably demonstrated decreased pulmonary expansion, symmetric generalized reticulogranular lung opacities, and air bronchograms. Refinements in perinatal medicine, including antenatal glucocorticoid administration, surfactant replacement therapy, and increasingly sophisticated ventilatory strategies have decreased the prevalence of RDS and air leak, altered familiar radiographic features, and lowered the threshold of potential viability to a gestational age of approximately 23 weeks. Alveolar paucity and pulmonary interstitial thickness in these profoundly premature neonates impair normal gas exchange and may necessitate prolonged mechanical ventilation, increasing the risk of lung injury. Bronchopulmonary dysplasia (BPD), alternatively termed *chronic lung disease of infancy*, is a disorder of lung injury and repair originally ascribed to positive-pressure mechanical ventilation and oxygen toxicity. Before the advent of surfactant replacement therapy, chest radiographs of infants with classic BPD demonstrated coarse reticular lung opacities, cystic lucencies, and markedly disordered lung aeration that reflected alternating regions of alveolar septal fibrosis and hyperinflated normal lung parenchyma. In the current era of surfactant replacement, BPD is increasingly a disorder of very low-birth-weight neonates with arrested alveolar and pulmonary vascular development, minimal alveolar septal fibrosis and inflammation, and more subtle radiographic abnormalities.

<http://radiographics.rsna.org/cgi/content/full/25/4/1047>

Radiographics July/August 2005

(\*del RadioGraphics y el Instituto de Patología de las Fuerzas Armadas)

\*Resúmenes enviados y publicados con autorización de la RSNA.



## From the archives of the AFIP

### Imaging of Musculoskeletal Liposarcoma with Radiologic-Pathologic Correlation<sup>1</sup>

Mark D. Murphey, MD • Lynn K. Arcara, MD • Julie Fanburg-Smith, MD

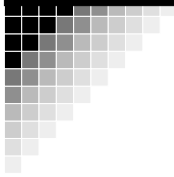
Liposarcoma is the second most common type of soft-tissue sarcoma, accounting for 10%-35% of these lesions. The World Health Organization has categorized soft-tissue liposarcomas into five distinct histologic subtypes: well differentiated, dedifferentiated, myxoid, pleomorphic, and mixed type. Well-differentiated liposarcomas frequently demonstrate a diagnostic appearance on computed tomographic (CT) or magnetic resonance (MR) images, with a largely lipomatous mass (> 75% of the lesion) and nonlipomatous components in thick septa or focal nodules. The CT or MR imaging finding of a nodular dominant focus (> 1 cm in size) of nonlipomatous tissue in a well-differentiated liposarcoma suggests dedifferentiated liposarcoma, and biopsy should be directed at the nonadipose component. The high water content of myxoid liposarcoma seen at pathologic analysis and constituting the majority of the lesion is reflected at sonography, CT, and MR imaging. However, the detection of a small amount of adipose tissue in the septa or as small nodular foci superimposed on the background of myxoid tissue allows prospective diagnosis in 78%-95% of myxoid liposarcomas. Pleomorphic liposarcomas are high-grade sarcomatous lesions and typically appear as heterogeneous soft-tissue masses, although small amounts of fat are seen on MR images in 62%-75% of cases, findings that suggest the diagnosis. Mixed-type liposarcomas have features representing a combination of the other subtypes. Primary liposarcoma of bone is exceedingly rare and usually demonstrates aggressive nonspecific features, although fat may be seen. Understanding and recognition of the spectrum of appearances of the various types of musculoskeletal liposarcoma, which reflect their underlying pathologic characteristics, improves radiologic assessment and is vital for optimal patient management.

<http://radiographics.rsna.org/cgi/content/full/25/4/1371>

Radiographics September/October 2005

(\*del RadioGraphics y el Instituto de Patología de las Fuerzas Armadas)

\*Resúmenes enviados y publicados con autorización de la RSNA.



## From the archives of the AFIP Oligodendroglioma and Its Variants: Radiologic-Pathologic Correlation<sup>1</sup>

Kelly K. Koeller, CAPT, MC, USN • Elisabeth J. Rushing, COL, MC, USA

Oligodendroglioma is the third most common glial neoplasm and most commonly arises in the frontal lobe. It occurs in males more frequently, and the peak manifestation is during the 5th and 6th decades. Children are affected much less commonly. The clinical presentation is often of several years duration with most patients presenting with seizures, reflecting the strong predilection of this tumor to involve the cortical gray matter. Current histopathologic classification schemes recognize two main types of tumors: well-differentiated oligodendroglioma and its anaplastic variant. Less commonly, neoplastic mixtures of both oligodendroglial and astrocytic components occur and are termed *oli-goastrocytomas*, with both well-differentiated and anaplastic forms. Surgical resection is the mainstay of initial treatment, and many patients experience a long progression-free period. Recent genotyping has revealed chromosomal loss of 1p and 19q as a genetic signature in most oligodendrogliomas, and these tumors respond favorably to chemotherapy. Hence, radiation therapy is now generally reserved for partially resected tumors and cases that failed to benefit from chemotherapy. At cross-sectional imaging, the tumor characteristically involves the cortical gray matter and frequently contains calcification. Robust enhancement is not a common feature and suggests transformation to a higher histologic grade. Advanced magnetic resonance imaging techniques and metabolic imaging play increasingly important roles in both pre and postoperative assessment of these complex neoplasms.

<http://radiographics.rsna.org/cgi/content/full/25/6/1669>

Radiographics November/December 2005